

Immediate Reconstruction of a Large Mandibular Defect of Locally Invasive Benign Lesions (A New Method)

Gholamreza Shirani, OMFS, DDS, MS,* Mahnaz Arshad, DDS,[†]
Farnoush Mohammadi, OMFS, DDS, MS*

Tehran, Iran

Locally invasive benign tumor and large lesions such as ameloblastoma, giant cell granuloma, odontogenic keratocyst, and odontogenic myxoma are a benign, invasive, lesions of the jaws that predominantly affects the mandible. Despite the benign nature of these lesions, there is a high rate of local recurrence after curettage, which usually requires resection. The traditional surgical approach for resection of these lesions, via either mandibulotomy or mandibulectomy is extraoral approach which is associated with significant functional and esthetic sequelae. A case series is presented here in which less invasive and intraoral approach. An intraoral approach provides wide and fast access to the mandible. This approach represents a less invasive alternative that provides access to the mandible for curative resection of benign tumors with minimal postoperative sequelae. At 5 years follow-up, there were minimal functional and esthetic defects.

We explored the use of the less invasive and more esthetic incision as an approach to resection and reconstruction of the mandible. It is our belief that these concerns have been best addressed by the minimally invasive procedure used in this report. This approach resulted in a minimal esthetic and functional defect even though a massive mandibular resection was performed.

Key Words: Mandible, intraoral, reconstruction

From the *Department of Oral and Maxillofacial Surgery of Tehran Medical Science University, and [†]Tehran Medical Science University, Tehran, Iran.

Address correspondence and reprint requests to Mahnaz Arshad, DDS, Department of Oral and Maxillofacial Surgery, Dental Faculty, Tehran Medical Science University, Tehran, Iran; E-mail: mehrnaz_arshad@yahoo.com

Reconstruction of large mandibular defects represents a challenge to head and neck reconstructive surgeons.¹ The mandible is both functionally and cosmetically one of the most important structures of the head and neck, contributing to facial contour, chewing, speech and swallowing.² The mandible plays a major role in airway protection and support of the tongue, lower dentition, and the muscles of the floor of the mouth permitting mastication, articulation, deglutition, and respiration.³ The most common indication for mandibular reconstruction remains ablative surgery for neoplastic lesions of the oral cavity and oropharynx. Other causes of mandibular defects include trauma, infection/inflammation, osteoradionecrosis, and congenital deformities.¹

When undertaking mandibular reconstruction, the restoration of bony continuity alone should not be considered the measure of success. The functions of chewing, swallowing, speech articulation, and oral competence must also be addressed. The ultimate goal of mandibular reconstruction is to return the patient to their previous state of function. In order to achieve this goal, the reconstructive surgeon must attempt to restore bony continuity and facial contour, maintain tongue mobility, and attempt to restore sensation to the denervated areas. Oral rehabilitation postoperatively is important to improve the patients' ability to manipulate the food bolus, swallow, and articulate speech. Dental rehabilitation must also be addressed.

The first step in undertaking mandibular reconstruction involves careful evaluation of the patients' anatomy in order to define the full extent of the existing or proposed defect. Both bony and soft tissue components must be examined so that the surgeon can conceptualize the tissue components which require reconstruction. The detailed definition of the defect provides the surgeon with a framework for selecting the best method for reconstruction.

When evaluating defects that involve the mandibular ramus, it is important to note if the patient

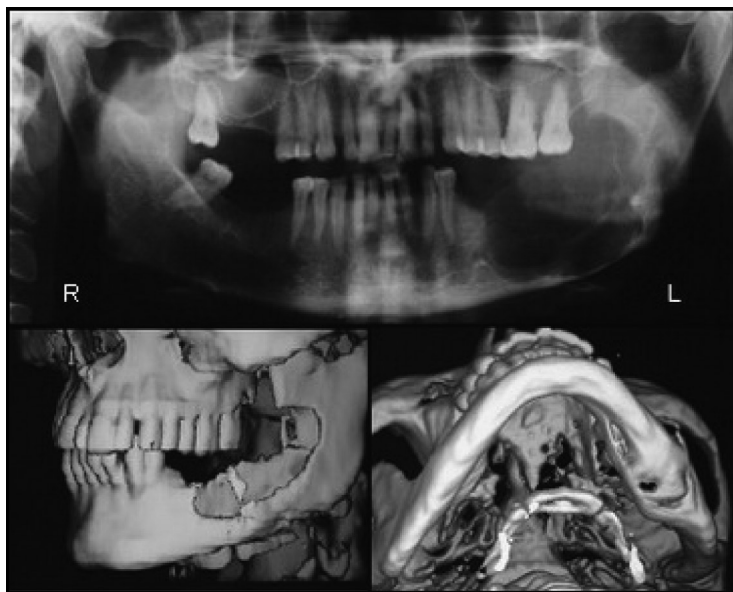


Fig 1 Radiographic appearance of lesion (patient 6).

has a proximal segment of bone, a functioning temporomandibular joint, or a condylar neck to which the graft may be secured. Radiographic analysis of the bony mandibular anatomy can be very helpful when formulating a plan for oromandibular reconstruction. Computed tomography (CT) with bone windows, three-dimensional CT, panoramic films, and magnetic resonance imaging add additional information in terms of amount of actual bone and soft tissue loss and the relationships of the remaining mandibular segments to the proposed and/or existing defect. When evaluating patients with existing mandibular defects, the quality and quantity of the remaining soft tissue is important.²⁻⁴

Advances in diagnostic technologies have enabled surgeons to perform minimally invasive procedures, avoiding the morbidity and esthetic sequelae associated with traditional therapeutic approaches for lesions in the head and neck.⁵ These cases present a novel approach to the curative treatment of mandibular large defect.

MATERIALS AND METHODS

Seven patients were referred to the Department of Oral and Maxillofacial Surgery of Shariati Hospital of Tehran Medical Science University from 2000 to 2005 with large lesions of mandible. The lesions were biopsied and the results of the biopsy were consistent with locally invasive benign lesions such as ameloblastoma, giant cell granuloma, odontogenic

keratocyst, odontogenic myxoma, and spindle cell tumor.

The technique used for reconstruction of the mandible involves exposure of the mandible with an intraoral incision 1 cm from the upper occlusal surface of the third molar. The flap was like sagittal split osteotomy, it continued with sulcular incision and with releasing incision in anterior to the lesion. The mucoperiosteal flap was elevated and dissected and mandible was totally exposed both lingually and buccally from posterior edge of ramus to anterior of lesion. We dissected all muscles and soft tissues, even on the coronoid and condylar process of the

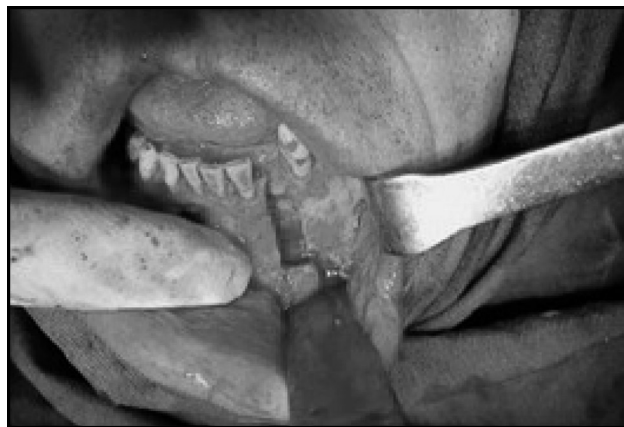

Fig 2 Anterior cut of lesion (note the step cut).

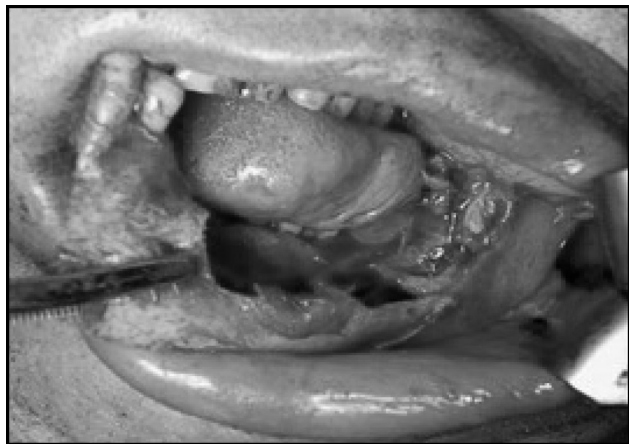

Fig 3 Wide dissection of proximal segment.

mandible. The bone was cut with an adequate safe margin related to kind of lesions on the anterior side (Figs 1 and 2), and the hemi mandible, which consists of lesion, condyle, coronoid, and ramus, was withdrawn (Figs 3 and 4).

So we formed unilock plate on the bone with minimal 3 holes on each sides of lesion (Fig 5). After precise adaptation of plate, the posterior edge of lesion was cut and condylar process was separated from the lesion. Then condylar process was connected to the plate with 3 screws as adapted previously.

We used iliac bone for mandibular reconstruction. After removing bone of iliac and putting the autograft in the cephalothin and gentamicin, we connected each segment of graft with 1 or 2 screws (Fig 6).

Then we guided condylar process with finger to the glenoid fossa. After that anterior portion of plate was fixed with 3 screws to anterior of mandible, then suturing was performed watertight from posterior to anterior (Figs 7–9). At last we applied to IMF with eyelet wiring for 2 to 3 weeks. In the first days, because of edema and hematoma the gap was seen between glenoid fossa and condylar process, but it was absorbed few days later (Fig 10).

He was discharged with no problems (Fig 11).

CLINICAL REPORTS

Patient 1

A 19-year-old male was referred with a large painless swelling of the right side of mandible that made second molar mobile and malposed. The lesion was firm and the nerve was intact. Panoramic radiography showed multilocular radiolucency that was from first premolar to ramus and resorption on first and second molars roots (Fig 12). The lesion was biopsied and the result of the biopsy was consistent with odontogenic myxoma. Then an intraoral mandibular reconstruction was done. Five years follow-up does not show any recurrence.

Patient 2

A 13-year-old female was referred with a large swelling of the right side of mandible. The intraoral lesion was sessile, with buccolingual expansion, and extraoral expansion on buccal and inferior border of mandible. There was paraesthesia on the right

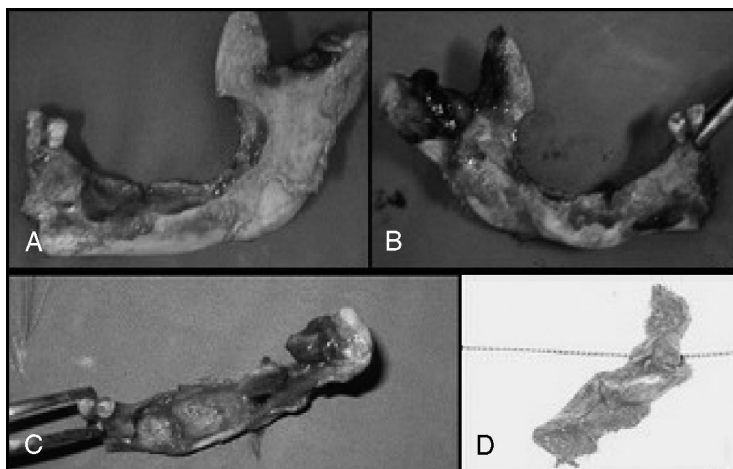


Fig 4 Appearance of hemi mandible from (A) buccal, (B) lingual, (C) above, and (D) view of lesion.

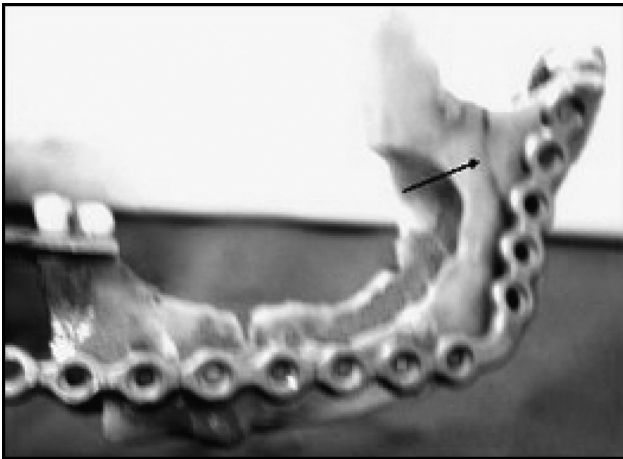


Fig 5 Precise adaptation of plate out of mouth before the cut of lesion from condyle.

side of mandible. Panoramic radiography showed multilocular radiolucency that was from first premolar to ramus (Fig 12). The lesion was biopsied and the result of the biopsy was consistent with spindle cell tumor. An intraoral mandibular reconstruction was done. Three year follow-up does not show any recurrence.

Patient 3

A 24-year-old female was referred with a large swelling of the right side of mandible. She notified to it after extraction of the first molar. The intraoral lesion was with buccolingual expansion and with extraoral expansion on buccal and the right inferior border of mandible and pogonion. Panoramic radiography showed unilocular radiolucency that was

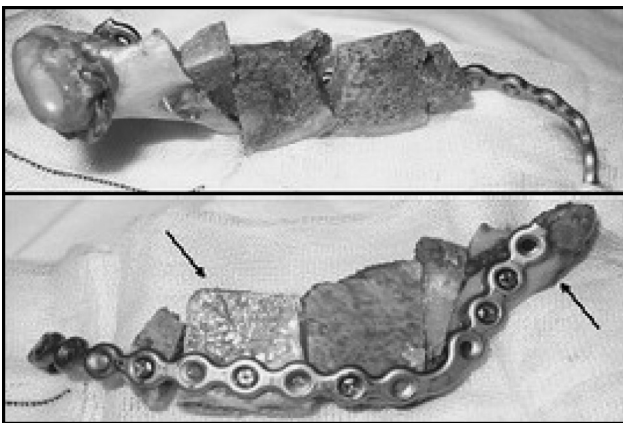


Fig 6 Set of condylar process and graft to plate.

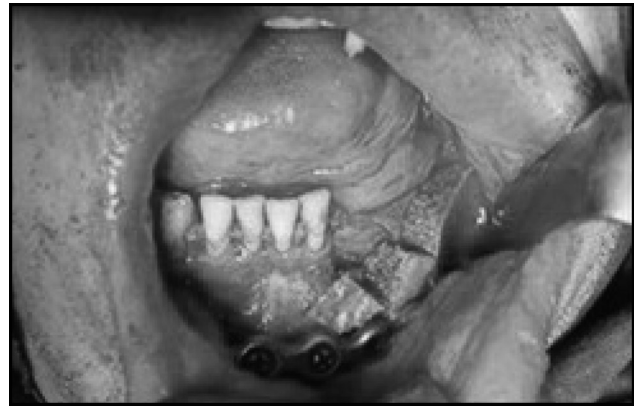

Fig 7 Install of condyle and reconstructed segment to the mouth and fix to anterior segment.

between canine and the first molar on that side (Fig 12). The lesion was biopsied and the result of the biopsy was consistent with plexiform ameloblastoma. Then an intraoral mandibular reconstruction was done. Three year follow-up does not show any recurrence.

Patient 4

A 21-year-old female was referred with a large swelling of the left side of mandible. The intraoral lesion was with buccolingual expansion and with extraoral expansion on buccal and the left inferior border of mandible. Panoramic radiography showed unilocular radiolucency between first premolar and impacted third molar on that side (Fig 12). The lesion was biopsied and the result of the biopsy was consistent with ameloblastoma. Then, an intraoral

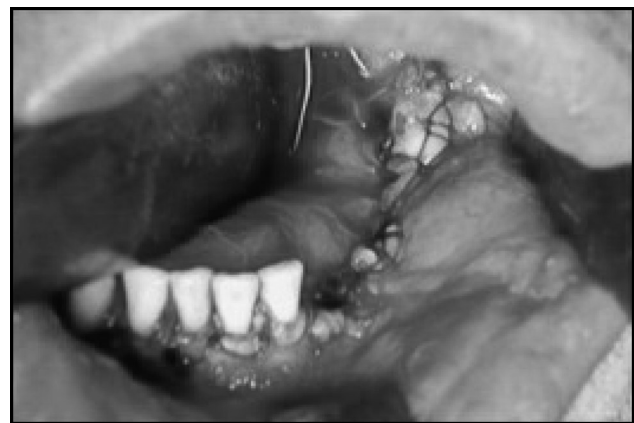

Fig 8 Water-tight suturing of intraoral incision.

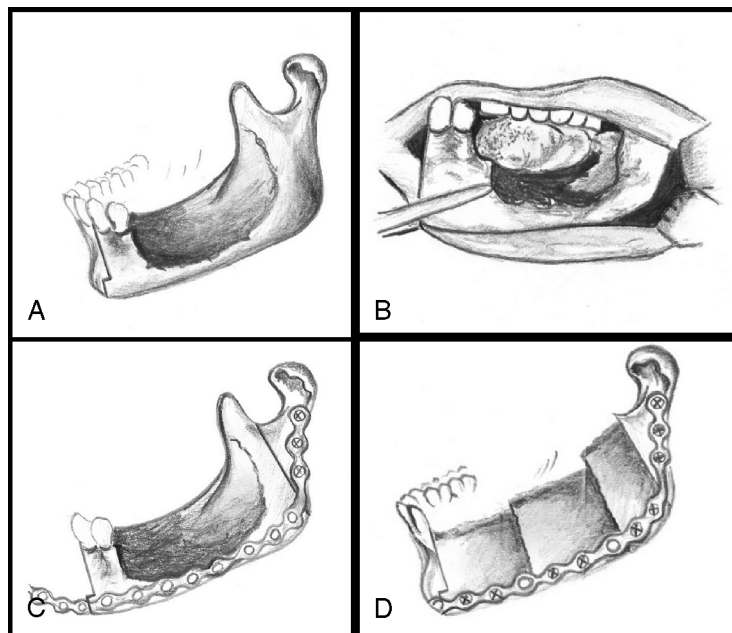


Fig 9 (A) Anterior cut of lesion (note the step cut), (B) Withdrawal of hemimandible with lesion intraorally, (C) Precise adaptation of plate out of mouth before cut of lesion from condyle, (D) Graft adaptation with condyle and anterior border of mandible.

mandibular reconstruction was done. One year follow-up does not show any recurrence.

Patient 5

A 23-year-old male was referred to our clinic because of swelling in posterior region of the left site of mandible. The patient reported pain and moderate swelling. The patient’s history was negative for any prior third molar extraction, cystectomy, or infection. The patient denied any neurosensory-deficit associated with the left inferior alveolar nerve. On clinical examination, there was moderate swelling on buccal

and lingual site of third molar and ramus. Aspiration was positive for cystic fluid and pus. The panoramic radiography showed a large, multilocular, radiolucent lesion that occupied most of the left mandibular ramus and coronoid process, extending from the neck of the condyle to the mandibular left second premolar

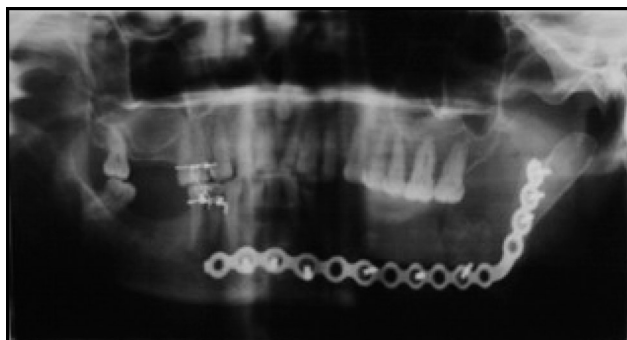

Fig 10 Postoperative panoramic view (one day after surgery).

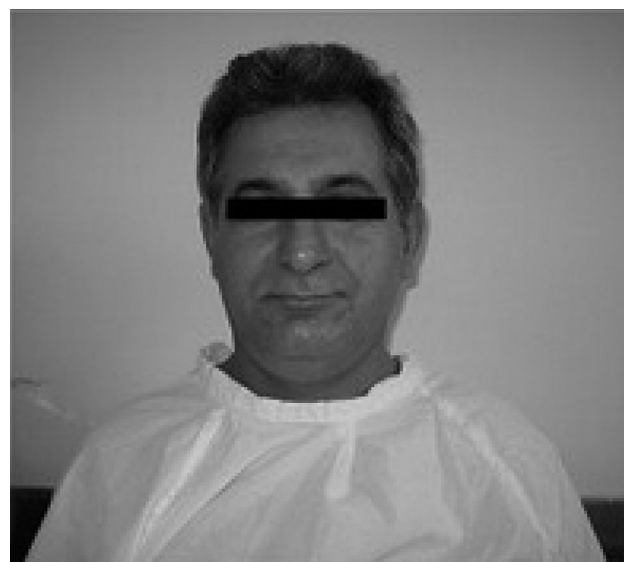

Fig 11 Appearance of patient after 2 months.

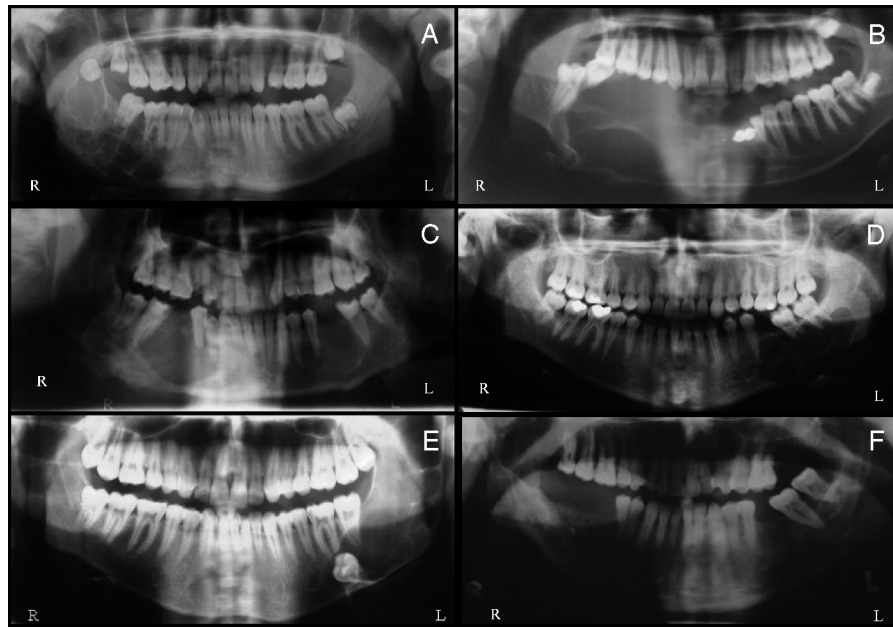


Fig 12 Radiographic appearances of the lesions. (A) patient 1, (B) patient 2, (C) patient 3, (D) patient 4, (E) patient 5, (F) patient 7.

with the impacted third molar (Fig 12). The lesion was biopsied and the results of the biopsy were consistent with an odontogenic keratocyst (OKC). Then, an intraoral mandibular reconstruction was done. One year follow-up does not show any recurrence.

Patient 6

A 46-year-old male was referred with a large, painless swelling of the left side of the mandible. He had a history of ameloblastoma approximately 2 years prior. Radiographs showed a large multilocular lesion on the left side of the mandible from canine to ramus (Fig 1). The lesion was biopsied and the result of the biopsy was consistent with recurrent ameloblastoma. Then, an intraoral mandibular reconstruction was done. Eight month follow-up does not show any recurrence.

Patient 7

A 26-year old male was referred with a large swelling of the right side of mandible. The patient didn't report any pain on that side. Radiography showed a large multilocular radiolucency on the right side of mandible from second premolar to condyle (Fig 12). The lesion was biopsied and the result of the biopsy was consistent with ameloblastoma. Then, an intraoral mandibular reconstruction

was done. Seven month follow-up does not show any recurrence.

DISCUSSION

The goals of mandibular reconstruction are: 1) establishment of mandibular continuity, 2) establishment of an osseous-alveolar base, 3) correction of soft-tissue defects, and 4) establishment of mandibular function.

Methods to restore mandibular defects can be classified into three basic categories: 1) alloplastic material, 2) alloplast with bone, and 3) autogenous bone. Autogenous bone grafts can be in the form of free bone transfer, pedicled osteomyocutaneous grafts, or microvascular free grafts. Reconstruction using free bone grafts has a high failure rate due to the lack of vascularization. Pedicled osteomyocutaneous grafts overcome the major problems associated with free bone grafts by supplying their own vascularity and soft tissue. These grafts, however, require an additional operation site, longer surgical time, and provide a limited amount of bone. These osteomyocutaneous grafts include the sternocleidomastoid, pectoralis major (5th rib), and trapezius grafts.²

The iliac crest provides a curved piece of bone of up to 16 cm in length. It is possible to fashion an ascending ramus using this graft without the need

for segmentalization of graft because of the wide flat shape. The iliac crest is also ideal for receiving osseointegrated implants.³

The extraoral approach has some advantages, specifically ease of reduction under good visibility. However, this method leaves a facial scar and has the potential to cause facial nerve damage. For these reasons, some surgeons have attempted an intraoral approach.⁵

Theoretically, removal and replantation of the condyle should result in inadequate vascularity, which can potentially lead to ischemic necrosis and resorption of the condyle. However, Choung and et al's⁵ clinical results have all shown adequate revascularization and satisfactory function postoperatively.

The traditional approach for a mandibulectomy has been widely used in the resection of head and neck tumors; it is associated with troublesome postoperative sequelae, including decreased lip sensation and mobility, as well as oral commissure incontinence. Esthetic sequelae include disfiguring scars, lip vermilion notching, and loss of chin pad contour.⁶

Although this intraoral approach would not be appropriate for the resection of malignant tumors, it is ideal for the removal of locally invasive benign tumors. It preserves oral competence and facial motor function and minimizes the esthetic and functional sequelae.

The advantages of this method are:

1. Possibility of removing and repositioning of the mandible intraorally
2. No facial scar
3. Both removal of lesion and reconstruction procedure simultaneous and result in better healing

4. Make more ideal contour of face
5. No damage to facial vein and artery, and less bleeding and hematoma
6. No damage to marginal mandibular nerve that innervate lips
7. Adaptation of the plate provides a better condylar position

For the patient with a benign resectable lesion and a long life expectancy, the functional and esthetic concerns of the resection and reconstruction are magnified. It is our belief that these concerns have been best addressed by the minimally invasive procedure used in this report. This approach resulted in a minimal esthetic and functional defect even though a massive mandibular resection was performed.

REFERENCES

1. Mehta RP, Deschler DG. Mandibular reconstruction in 2004: an analysis of different techniques. *Current Opinion in Otolaryngology & Head and Neck Surgery* 2004;12:288-293
2. Lyos AT. Mandibular Reconstruction. 1993 February. From: <http://www.bcm.edu/oto/grand/21893.html>. Accessed October 11, 2007
3. Clements KS. Mandibular Reconstruction. 1997 April. From: <http://www.utmb.edu/otoref/grnds/mandibrecon.htm>. Accessed October 11, 2007
4. Choung P-H, Nam I-W. An intraoral approach to treatment of condylar hyperplasia or high condylar process fractures using the intraoral vertico-sagittal ramus osteotomy. *J Oral Maxillofac Surg* 1998;56:563-570
5. Derderian CA, Gurtner GC, McCarthy JG. Reconstruction of a large mandibular defect utilizing temporary zygomatic-ramal fixation and bilateral risdon incisions. *J Craniofac Surg* 2004; 15(1):16-19
6. Rapidis AD, Valsamis S, Anterriotis DA, et al. Functional and aesthetic results of various lip-splitting incisions: a clinical analysis of 60 cases. *J Oral Maxillofac Surg* 2001;59:1292-1296