

7. Wen-ching E, Huanh CS, Chen YR. Temporomandibular joint reconstruction in children using costochondral graft. *J Oral Maxillofac Surg* 1999;57:789-798
8. Ko W-C, Huang C-S, Chen Y-R. Temporomandibular joint reconstruction in children using costochondral grafts. *J Oral Maxillofac Surg* 1999;57:789-798
9. Raustia A, Pernu H, Pyhtinen J, et al. Clinical and computed tomographic findings in costochondral grafts replacing the mandibular condyle. *J Oral Maxillofac Surg* 1996;54: 1393-1400

Massive Repeated Nose Bleeding After Bimaxillary Osteotomy

Ali Manafi, MD,* Hossein Ghenaati, MD,[†]
Farideh Dezhm, MD,[†] Mahnaz Arshad[‡]

Tehran, Iran

Abstract: In LeFort I surgery, the separation of the pterygomaxillary junction is done by osteotomy. Although the osteotome is positioned too close to the maxillary artery and its branches during pterygomaxillary separation, postoperative complications from vascular injuries are uncommon. We describe an unusual occurrence of a maxillary artery pseudoaneurysm after LeFort I and bilateral sagittal split osteotomies for maxillary advancement and mandibular setback as well as (anterior sliding) genioplasty. In a patient with class III occlusion and midface retrusion, the significant bleeding began 10 days postoperatively, which was controlled by anterior and posterior nasal packing. The bleeding recurred 28 days after surgery; thus, vascular anatomy in the pterygomaxillary area is reviewed, pseudoaneurysm was diagnosed on selective carotid angiography and successfully treated by embolization; and 2-year follow up was uneventful.

Key Words: LeFort I, pseudoaneurysm, late complication

Aneurysm is abnormal focal dilation of an arterial wall. True aneurysms involve all three components (i.e., intima, media, and adventitia) of the arterial wall and are most frequently associated with atherosclerosis; whereas traumatic aneurysms are usually the result of blunt or penetrating trauma with injury to the arterial wall; however, the effused blood is retained by the surrounding tissues.¹ The blood enters the tissues through the persistent opening during systole, confined only by the fascia, and it keeps filling the space until the pressure in the

hematoma is large enough to counterbalance the arterial pressure and tamponade the area. As a result, further extravasation will stop or diminish.^{2,3} The hematoma will subsequently undergo clot formation and retraction and will liquefy in the center and produce a cavity.^{1,4} Pseudoaneurysms usually occur within 1 to 8 weeks postinjury to the vessel and may result in asymmetry, neurologic defects, and possible release of embolic thrombi.¹ The velocity of their appearance depends on the arterial defect and the nature of the adjacent tissues. The variable time period dictates the temporal sequence of events leading to the clinical manifestations of eventual rupture and hemorrhage.⁵ Besides respiratory embarrassment, arterial hemorrhage is the most serious complication of maxillofacial trauma. Although the facial region has an abundant vascular supply, major life-threatening hemorrhage after maxillofacial trauma is uncommon.¹

CLINICAL REPORT

A 42-year-old woman was referred to our clinic with class III occlusion and midface retrusion (Fig 1).

During bimaxillary surgery, LeFort I and bilateral sagittal split osteotomies for maxillary advancement and mandibular setback, respectively, as well as (anterior sliding) genioplasty were performed. The operation lasted 4 hours, and there was no problem during the operation. All osteotomized areas were fixed with plates and screws in the new place. The patient's teeth were placed in neutral occlusion with an interdental splint. Bleeding was scant, and there was no need for transfusion. When the nasotracheal tube was gently removed, there was a minimal amount of bleeding that stopped spontaneously. After surgery, two nasopharyngeal tubes were inserted and the patient's mouth was opened.

The next day, in the morning, the nasopharyngeal tubes were removed and clear liquid feeding

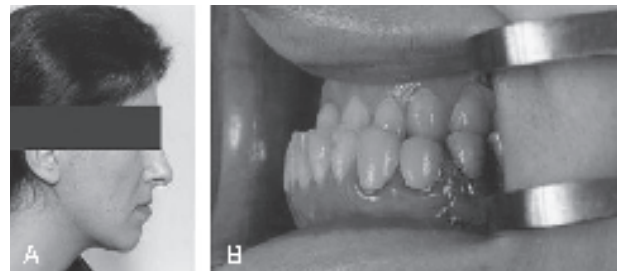


Fig 1 Preoperative views demonstrating class III occlusion and midface retrusion: (A) right lateral view, (B) left lateral view of teeth shows reverse overbite.

From the *Department of Plastic Surgery and [†]Department of Radiology, Iran University of Medical Sciences; and [‡]Dentistry Faculty of Tehran University of Medical Science, Tehran, Iran.

Address correspondence and reprint requests to Ali Manafi, MD, P.O. Box 13185-1678, Tehran, Iran; E-mail: ocrct@sina.tums.ac.ir

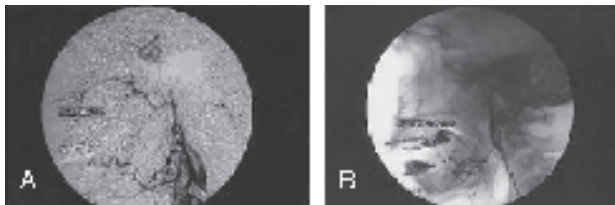

Fig 2 (A) Left lateral radiographic projection demonstrating the microcatheter injection into the right internal maxillary artery. The central collection of contrast indicates a pseudoaneurysm. (B) Postembolization view.

was started. On the third day after surgery, the patient was discharged in good general condition. On the tenth day, in the bathroom, she had nose bleeding that stopped spontaneously. She was referred to the emergency room of the hospital and anterior nasal packing was performed. After 2 days, the packing was withdrawn; 48 hours later, nasal bleeding began again during bathing but stopped before the patient reached the hospital.

No active bleeding was found during exploration in the operating room and combined anterior and posterior nasal packing were removed uneventfully. Routine tests were performed. Hemoglobin had not dropped, and coagulation tests were normal. Consultation with a hematologist was performed. In his opinion, there was no need for more examinations. Twelve days later, the patient's bleeding started again, but before the patient reached the hospital, the bleeding stopped. At the hospital, anterior and posterior nasal packing was performed and the patient was admitted to the hospital and immediate digital subtraction angiography was performed.

The angiography demonstrated a pseudoaneurysm of the internal maxillary artery close to the LeFort I osteotomy. Selective embolization with 300 μ m polyvinyl acetate was performed to control the bleeding in terminal branches of the external carotid artery (Fig 2). The patient experienced severe pain in the left side of her face; after 48 hours, she was discharged. She has had no problem 2 years later. The pain mainly disappeared after 3 months; it was related to the hypoperfusion of tissues in the embolized area. One year after the first operation, miniplates and screws were removed (Fig 3).

Two-year follow up was uneventful.

DISCUSSION

Pseudoaneurysms, which are in the head and neck regions, are usually encountered in large-diameter

vessels. The majority arise from either the common or the internal carotid arteries.² False aneurysms of the external carotid territory disproportionately involve the temporal and facial arteries because of their large vessel diameter and long, superficial course.³ Conversely, the internal maxillary artery (IMA) and its tributaries are rarely involved because of their relatively small caliber and deep location.

The internal maxillary artery, the larger terminal branch of the external carotid, arises behind the mandibular neck, at first embedded in the parotid gland; it then passes medial to the mandibular neck; and superficial or deep to the lower head of the lateral pterygoid to reach the pterygopalatine fossa, it has mandibular, pterygoid, and pterygopalatine segments.

The mandibular segment of the IMA gives rise to deep auricular tympanic, middle meningeal, accessory meningeal, and inferior alveolar branches.

This first portion of the IMA, particularly the inferior alveolar branch, is vulnerable to damage during mandibular osteotomies.^{5,6}

The pterygoid segment of the IMA gives off branches that supply the muscle of mastication and the buccinator muscle passing through the pterygomaxillary fissure into the pterygopalatine fossa. Osteotomy during pterygomaxillary separation risks the IMA and branches at this junction. Acute bleeding from a transected vessel usually tamponades or is controlled surgically. The partially injured (later torn) vessel wall leads to a weak point in the vessel wall usually resulting in formation of a pseudoaneurysm.^{5,6}

The pterygopalatine part passes between the heads of the lateral pterygoid and through the pterygomaxillary fissure into the pterygopalatine fossa, where it is situated anterior to the pterygopalatine ganglion.⁶

LeFort I osteotomy is generally thought to be a safe procedure; complications occur in 6% to 9% of

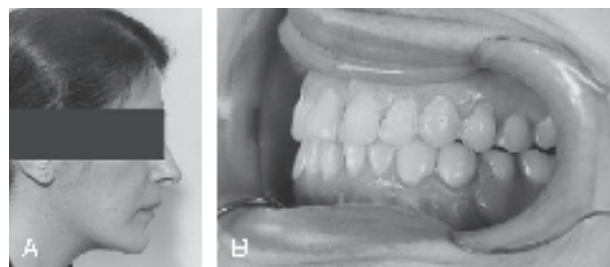


Fig 3 One-year postoperative views: (A) right lateral view; (B) left lateral view of teeth shows normal overbite and normal occlusion.

cases. Manipulation of the bones of the base of the skull during surgery may inadvertently cause damage to the vessels. Any procedure that requires manipulation of the skull base will never be completely free from potentially devastating visual and neurologic complications.⁷

Complete excision of the pseudoaneurysms with ligation of the proximal and distal portions of the artery is the recommended treatment, although this may be difficult because of vessel retraction.⁸ Other forms of treatment include superselective arterial embolization. Embolization is a less invasive method than traditional surgical techniques.¹

Our patient with class III occlusion and midface retrusion was embolized successfully and up to now, more than 2 years postoperatively, she has not had any problems.

REFERENCES

1. Zachariades N, Rallis G, Papadentricu G, et al. Pseudoaneurysms and transaction of facial vessels. *Oral Surg Oral Med Oral Pathol* 2001
2. Hemming SB, Johnson RS, Ferrado N. Management of a ruptured pseudoaneurysms of the sphenopalatine artery following a Le Fort I osteotomy. *J Oral Maxillofac Surg* 1987; 45:533-536
3. Gerbino G, Rocca F, Grosso M, et al. Pseudoaneurysms of the internal maxillary artery and Frey's syndrome after blunt facial trauma. *J Oral Maxillofac Surg* 1997;55:1485-1490
4. Lutcavage GJ. Traumatic facial artery aneurysm and arteriovenous fistula: case report. *J Oral Maxillofac Surg* 1992;50:402-405
5. Bradley JP, Elahi M, Kawamoto HK. Delayed presentation of pseudoaneurysm after Le Fort I osteotomy. *J Craniofac Surg* 2002;13:746-750
6. Williams P, Warwick R, Dyson M, et al. *Anatomy*, 37th ed. New York: Churchill Livingstone, 1989
7. Bendor-Samuel R, Chen YR, Chen PK. Unusual complications of the Le Fort I osteotomy. *Plast Reconstr Surg* 1995;96: 1289-1296
8. Webber CM, Wind GG, Burton RG. Pseudoaneurysm of the superficial temporal artery: report of a case. *J Oral Maxillofac Surg* 1997;55:166-168

Cavernous Vascular Tumor of the Accessory Parotid Gland

Cheol-Ho Chang, MD, Goo-Hyun Mun, MD, So-Young Lim, MD, Won-Sok Hyon, MD, Sa-Ik Bang, MD, Kap-Sung Oh, MD

Seoul, Korea

From the Department of Plastic Surgery, Samsung Medical Center, Sungkyunkwan University, School of Medicine, Ilwondong, Gangnam-gu, Seoul, South Korea.

Address correspondence and reprint requests to Goo-Hyun Mun, MD, Department of Plastic Surgery, Samsung Medical Center, Sungkyunkwan University, School of Medicine, Ilwondong 50, Gangnam-gu, Seoul, South Korea 135-710; E-mail: gh.mun@samsung.com

Abstract: Accessory parotid gland tumors are uncommon and account for only 1% to 7.7% of all parotid gland tumors. Only one case report of hemangioma of the accessory parotid gland in infancy has been issued, and no report is available on this condition in an adult. We present the case of a 44-year-old woman with an accessory parotid gland tumor, which was finally diagnosed as a cavernous hemangioma histopathologically.

Key Words: Accessory parotid gland, cavernous hemangioma, hemangioma, vascular anomalies, vascular malformation

According to autopsy studies, the accessory parotid gland is present in 21% or 56% of the population. Their sizes range from that of a small, flattened pea to the size of a large lima bean. The accessory parotid gland is clearly separate from the main parotid gland and is located on the masseter muscle, to which it is bound by an extension of the masseteric fascia, and on or above the Stensen duct, into which it drains through one, or occasionally more than two, ducts.^{1,2}

Neoplastic changes within the accessory parotid gland are uncommon, and these neoplasms account for only 1% to 7.7% of all parotid gland tumors. Pleomorphic adenoma is the most common neoplasm as is the case for the main parotid gland. The malignancy rate of accessory parotid gland tumors ranges from 26% to 50% and is larger than that of the main parotid gland.^{3,4} Hemangiomas are the most common tumor of the main parotid gland in children; however, only one case report is available on infantile hemangioma of the accessory parotid gland.⁵ Furthermore, to the best of our knowledge, no case of hemangioma arising from the accessory parotid gland in an adult has been reported. We present such a case and include a review of the literature.

MATERIALS AND METHODS

A 44-year-old woman was referred to the authors' clinic because of a painless left midcheek mass with a 5-year history, which had recently increased in size. A physical examination revealed a firm mass approximately 1.5 cm in size in the region of the left anterior midcheek. It was not tender and was mobile without apparent adhesion to adjacent structures, and there was no evidence of sensory deficit or facial nerve palsy. A computed tomographic scan demonstrated a 1.2-cm well-demarcated ovoid soft tissue lesion on the lateral aspect of the left masseter muscle (Fig 1). The lesion was surrounded by accessory parotid tissue and showed poor enhancement. The first impression of the radiologist was of a benign