



# Dental rehabilitation of a cleft lip and palate patient by implant-supported overdenture: A case report

Mahnaz Arshad<sup>1</sup> | Narges Ameri<sup>1</sup> | Abdolreza Heidari<sup>2</sup> | Gholamreza Shirani<sup>3</sup>

<sup>1</sup>Department of Prosthodontics, Dental Research Center, Dentistry Research Institute, School of Dentistry, Tehran University of Medical Sciences, International Campus, Tehran University of Medical Sciences, Tehran, Iran

<sup>2</sup>Tehran University of Medical Sciences, Tehran, Iran

<sup>3</sup>Department of Oral and Maxillofacial Surgery, Dental Research Center, Dentistry Research Institute, School of Dentistry, Tehran University of Medical Sciences, Tehran, Iran

## Correspondence

Narges Ameri, School of Dentistry, International Campus, Tehran University of Medical Sciences, Tehran, Iran.  
Email: narges\_ameri@yahoo.com

## Abstract

Our patient was a 27-year-old male with a unilateral cleft lip and palate. Considering the mobility of bone segments around the cleft, an implant-supported removable overdenture (obturator) was fabricated, which improved the function and esthetics and led to patient satisfaction. The treatment results are still satisfactory after 5 years of follow-up.

## KEYWORDS

case report, cleft lip, cleft palate, osseointegrated implants, overdenture

## 1 | INTRODUCTION

Cleft lip and palate (CLP) is the second most common congenital anomaly, which is associated with complications such as esthetic deformities, oral abnormalities, and problems in deglutition, speech, and growth.<sup>1</sup> Management of CLP patients is challenging for physicians and dental clinicians. Also, CLP patients often experience psychological problems in addition to physical complications.<sup>2</sup>

Treatment of CLP patients is a long-term process and must continue until the completion of growth and development.<sup>3</sup> During the course of treatment, many patients benefit from alveolar bone grafting and orthodontic treatment. However, the need for prosthodontic treatments is often minimal, if any. Nonetheless, denture is considered as the ultimate treatment for some cases.<sup>4</sup>

Considering the congenital deformities, alveolar bone grafting is imperative for dental rehabilitation of CLP patients. However, alveolar bone grafting is not performed or fails in some patients. Also, alveolar bone grafting may not be suitable for some other patients due to the large size of the defect.<sup>1,5</sup>

Oral rehabilitation of CLP patients often includes replacement of the missing teeth. The use of dental implants is a reliable and predictable treatment option for this purpose. Dental implants enable efficient dental rehabilitation in patients in whom conventional prosthetic restoration could not yield satisfactory results.<sup>1,5</sup>

Dental implants can result in acceptable esthetics and improved retention, stability, and function of prosthetic restorations when used for dental rehabilitation of CLP patients. However, the implant survival rate in patients with cleft palate is lower than that in noncleft individuals. The 5-year

survival rate of implants in CLP patients ranges from 80% to 96% with a mean value of 88.6%.<sup>5,6</sup>

The appropriate time for implant placement in most CLP patients is after completion of the growth period and around 4-6 months after bone grafting.<sup>6</sup> Despite the fact that surgeons recommend early interventions with the new surgical techniques, many older patients could not benefit from such interventions (as in our present case). On the other hand, postsurgical defects such as residual oronasal fistula require prosthetic obturators. Despite the availability of many prosthetic options for CLP patients, removable dentures are the only available option for obstruction of such defects.<sup>7</sup> This case report describes prosthetic dental rehabilitation of a CLP patient by the use of an implant-supported overdenture (obturator).

## 2 | CASE REPORT

Our patient was a 27-year-old Iranian male with CLP who presented to the Prosthodontics Department of School of Dentistry, Tehran University of Medical Sciences. The patient had no history of cigarette smoking or alcohol consumption. He was dissatisfied with his appearance due to the absence of anterior teeth and was reluctant to smile.

The patient had a history of left side CLP, which had been surgically closed by bone grafting at 18 months of age; however, he still had leakage of oral fluids into his nose. Six months after bone grafting, he had received three implants at the site of central incisors and left lateral incisor (3.4 mm diameter, Implantium). The implant placed at the site of left

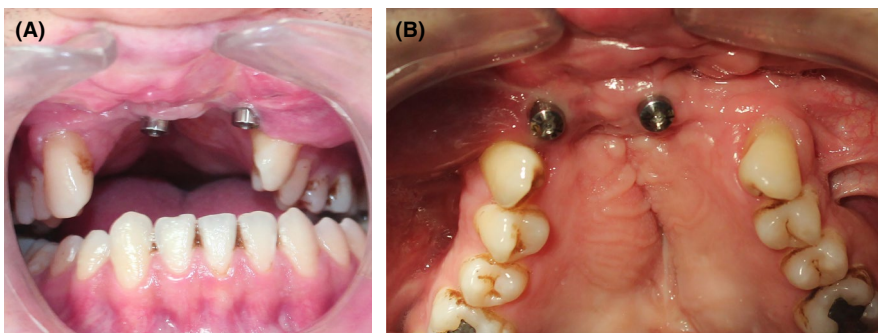
central incisor had failed and exfoliated 4 months after placement (Figure 1A).

On clinical examination, the movement of bone segments between the two implants was easily noticeable, and signs of the cleft were still visible in the soft tissue unilaterally and at the hard palate median raphe (Figure 1B).

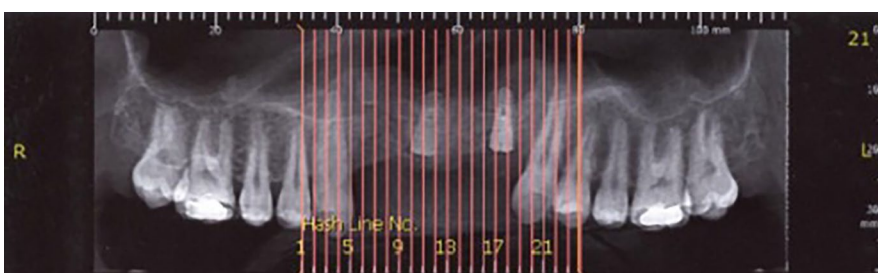
The available treatment plans were thoroughly discussed with the patient. Implant-supported fixed partial denture required bone grafting and implant placement (Figure 2), which was not accepted by the patient. Also, considering the mobility of bone segments, this treatment option had a poor prognosis. Thus, a treatment plan based on the present two implants was suggested. It was decided to fabricate an obturator-overdenture for the patient to obstruct the oronasal fistula while rehabilitating the dentition. Therefore, an implant-supported overdenture with ball attachment and palatal extension was designed to meet both the esthetic and functional requirements of the patient.

Primary impressions were made of both jaws using irreversible hydrocolloid material and prefabricated trays. A special tray was fabricated of auto-polymerizing acrylic resin to make a final impression of the maxilla. The tray was border molded using green modeling plastic impression compound (Kerr Corp.). The final impression was made using impression copings and polyvinyl siloxane impression material (Panasil, Kettenbach) via the direct technique. The analogs were tightened, and the master cast was poured with improved stone (Begostone; Bego).<sup>5</sup>

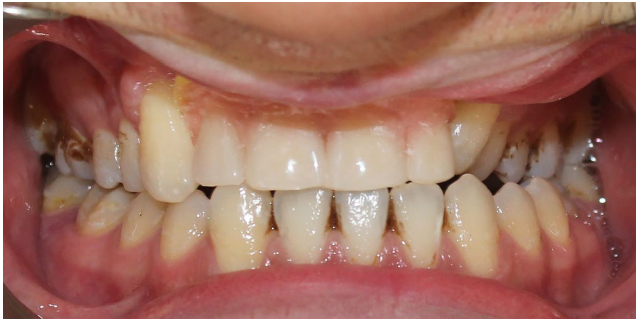Diagnostic tooth setup was performed and tried-in (Figure 3). Next, a putty index was obtained of the teeth on the cast for space analysis (Figure 4). Considering the position of



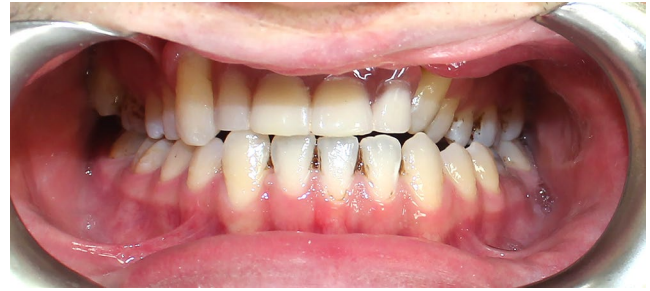**FIGURE 1** Intraoral view of the maxilla; (A) frontal (B) occlusal



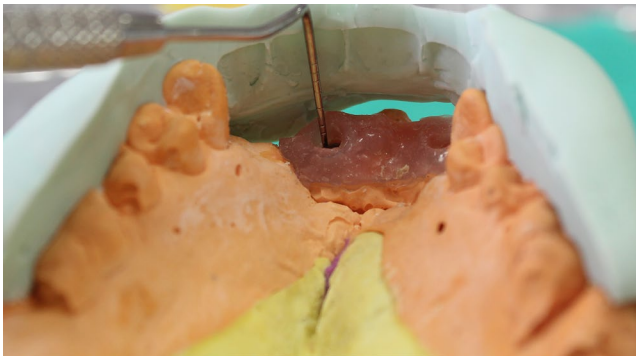**FIGURE 2** Radiographic view



**FIGURE 3** Tooth setup try-in



**FIGURE 6** Intraoral view of the final overdenture



**FIGURE 4** Assessment of interocclusal space and implant angulations by a putty index obtained from the tooth setup

implants and the available vertical space, ball abutments were selected for the overdenture. For framework fabrication, the undercut areas on the master cast were blocked-out, the cast was duplicated, and the framework was fabricated in the form of holder support.

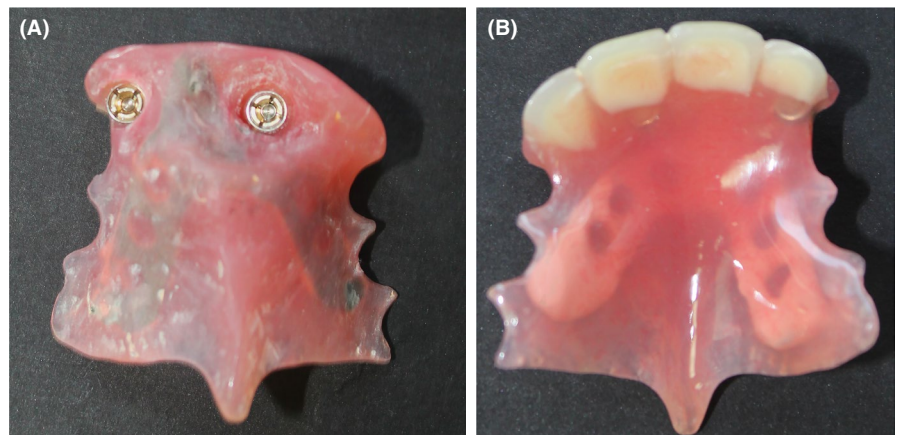
Tooth setup was performed again in the presence of framework and attachment, and tried-in. It was then waxed up and processed using heat-polymerizing acrylic resin (Meliodent; Heraeus Kulzer) (Figure 5). The overdenture was tried-in, and its extension, occlusion, and patient's speech were evaluated (Figure 6). The overdenture significantly improved the patient's speech and esthetics. The follow-ups were scheduled

at 1 day, 1 week, 1 month, and yearly afterward, following delivery.<sup>5</sup> It has been 5 years since the delivery, and the patient attends regular follow-up visits annually with no complications.

### 3 | DISCUSSION

Prosthetic replacement of the missing maxillary anterior teeth is an important step in oral rehabilitation of CLP patients. Wegscheider et al described several treatment options for prosthetic dental rehabilitation of CLP patients including fixed partial dentures (prosthetic crowns and bridges, Maryland bridge), removable dentures (conventional cast partial overdentures and complete dentures), and precision prostheses (appliances with bars, splints, and telescopic retainers).<sup>8</sup>

In carefully selected cases, dental implants can enhance the retention, stability, and occlusal function of prostheses.<sup>5</sup> Prior to implant placement, bone grafting is required in CLP patients to close the alveolar cleft. However, it may not be successful due to the high volume of the required bone. Other problems against implant placement in CLP patients include inappropriate labial cortical bone contour, poor quality of bone, and proximity to the nasal cavity and maxillary sinuses.<sup>2</sup> In our patient, bone grafting had been performed prior to implant placement. Nonetheless, the implant placed



**FIGURE 5** Final overdenture; (A) tissue surface, (B) external surface

at the site of left maxillary central incisor had failed and exfoliated prior to the prosthetic phase, which was probably due to the poor quality and quantity of bone in this region, close vicinity of the implants to the cleft, impaired blood circulation in the region after surgery, and micromovements of bone.<sup>7</sup> Also, many CLP patients undergo several surgical procedures during their adolescence and may not be able to physically or psychologically tolerate further surgical procedures for bone grafting and implant placement, as it was the case in our patient.<sup>2</sup>

Since the bone segments were mobile in our patient, treatment with fixed partial denture would increase the load applied to implants due to splinting of components. Overdenture seemed to be the best choice for our patient since it did not require splinting of components and would allow their movement. The patient could remove the denture at night. Also, the oral hygiene could be more easily practiced and the obturator would obstruct the oronasal fistula. Moreover, due to the large volume of the lost hard and soft tissue, fixed partial denture cannot yield ideal esthetic results in many cases. On the other hand, implant-supported overdenture can provide favorable support for the lips due to the presence of flanges and yield more favorable results. Also, it can obstruct the cleft area and improve the speech as such.

The retention and stability provided by implants depend on the location and number of implants as well as the type of attachment system used for implant-prosthesis connection.<sup>9</sup> Several attachment systems have been proposed for implant-supported maxillary overdentures such as the continuous bar for splinting of implant abutments and a combination of external resilient attachments and Hader clips, use of O-rings, and ball attachment.<sup>10</sup> The use of Hader and Dolder bar that extends over the mobile premaxilla can provide adequate retention and stability, given that the anterior extension of the arch formed by the bar does not apply inappropriate torque to the most anterior implant. Nonetheless, considering the rigidity of the complex of bone and osseointegrated implant, bar can apply excess load and stress to the implants and their surrounding bone, and lead to abutment screw loosening, implant or screw fracture, and risk of adverse biological reactions.<sup>11</sup> For our case, the use of individual resilient ball attachments was preferred to bar attachment.

Fabrication of implant-supported bar for retention and support of overdenture results in equal distribution of occlusal loads between the implants. However, bar attachment increases the surface area for plaque accumulation as well as the patient's cost, and prolongs the course of treatment.<sup>7</sup> In our patient, due to the mobility of the bone segments, the use of bar attachment would result in application of destructive forces to the implants following the movement of segments, due to the splinting of implants. Therefore, an implant-retained, tissue-supported overdenture with ball

attachments was fabricated to obstruct the oronasal fistula, decrease the loads applied to the implants, and lower the treatment costs.

Also, the use of light retention prevents the application of off-axial loads to the implants. Moreover, the flexible and compressible retainers distribute the lateral loads between the implants and the soft tissue. When a single elastic retainer is compressed following the movements of the denture, the other retainers are also involved and the elastic parts are compressed. Thus, the movements of the overdenture are balanced and the loads are transferred to all implants as well as the soft tissue. Furthermore, the use of light retention allows easier retrieval for enhanced cleaning and maintenance of the overdenture. More rigid denture retainers transfer all or a large portion of the loads directly to the supporting implants and can apply off-axial forces to the implants.<sup>7</sup>

## 4 | CONCLUSION

In this paper, we described successful prosthetic dental rehabilitation of a CLP patient with maxillary anterior edentulism by fabrication of an implant-supported overdenture (obturator). Fabrication of this overdenture improved the speech, esthetic appearance, and lip contour of the patient and obstructed his oronasal fistula with minimal complication, low cost, and enhanced maintenance.<sup>7</sup>

## CONFLICT OF INTEREST

The materials used in this case report are mentioned for clinical study purposes only. The authors do not have any financial interest in the companies whose materials are included in this article.

## AUTHOR CONTRIBUTIONS

MA: involved in the study conception and design, material preparation, prosthodontic treatment of patient, and revised the manuscript; NA: involved in material preparation and wrote the first draft of the manuscript; AH: involved in prosthodontic treatment of patient; GS: involved in the study conception and design, material preparation, and surgical treatment of patient.

## ORCID

Mahnaz Arshad  <https://orcid.org/0000-0002-6278-6278>

Narges Ameri  <https://orcid.org/0000-0001-5859-759X>

Gholamreza Shirani  <https://orcid.org/0000-0002-6229-1320>

[org/0000-0002-6229-1320](https://orcid.org/0000-0002-6229-1320)

## REFERENCES

1. Bousdras VA, et al. Esthetic and functional rehabilitation in patients with cleft lip and palate. *Ann Maxillofac Surg*. 2015;5(1):108-111.

2. Acharya V, Brecht LE. Conventional prosthodontic management of partial edentulism with a resilient attachment-retained overdenture in a patient with a cleft lip and palate: a clinical report. *J Prosthet Dent.* 2014;112(2):117-121.
3. Moore D, McCord JF. Prosthetic dentistry and the unilateral cleft lip and palate patient. The last 30 years. A review of the prosthodontic literature in respect of treatment options. *Eur J Prosthodont Restor Dent.* 2004;12(2):70-74.
4. Craven C, Cole P, Hollier L, Stal S. Ensuring success in alveolar bone grafting: a three-dimensional approach. *J Craniofac Surg.* 2007;18(4):855-859.
5. Hakan Tuna S, Pekkan G, Buyukgural B. Rehabilitation of an edentulous cleft lip and palate patient with a soft palate defect using a bar-retained, implant-supported speech-aid prosthesis: a clinical report. *Cleft Palate Craniofac J.* 2009;46(1):97-102.
6. Wermker K, et al. Dental implants in cleft lip, alveolus, and palate patients: a systematic review. *Int J Oral Maxillofac Implants.* 2014;29(2):384-390.
7. Flanagan D. An implant-retained maxillary overdenture to obturate a patent oronasal communication: a case report. *J Oral Implantol.* 2009;35(1):12-17.
8. Wegscheider W, et al. The system of prosthetic treatment for CLAP patients. *J Craniomaxillofac Surg.* 1989;17(Suppl 1):49-51.
9. Sigurgeirdottir E, Minsely GE, Rothenberger SL. Incorporation of an ERA attachment for obturator framework design: a clinical report. *J Prosthet Dent.* 2002;87(5):477-480.
10. Murat S, Gurbuz A, Genc F. Prosthetic rehabilitation of a patient with bilateral cleft lip and palate using osseointegrated implants and extracoronary resilient attachments: a case report. *Cleft Palate Craniofac J.* 2011;48(3):342-347.
11. Skalak R. Biomechanical considerations in osseointegrated prostheses. *J Prosthet Dent.* 1983;49(6):843-848.

**How to cite this article:** Arshad M, Ameri N, Heidari A, Shirani G. Dental rehabilitation of a cleft lip and palate patient by implant-supported overdenture: A case report. *Clin Case Rep.* 2020;00:1–5. <https://doi.org/10.1002/ccr3.3032>